

DISRUPT
CAD POOLED
DISRUPTIVE EVIDENCE
 IVL Effectiveness in Nodular & Eccentric Calcium

Patient-level pooled analysis of OCT sub-studies from CAD I, II, III, & IV represents the largest analysis of OCT outcomes of any calcium modification tool

By the Numbers

262

Patients

98.4%

Severe Ca++

43mm

Calcified Length

68%

Visible IVL Fractures

6mm²

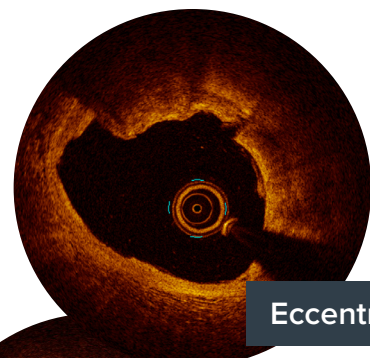
MSA

103%

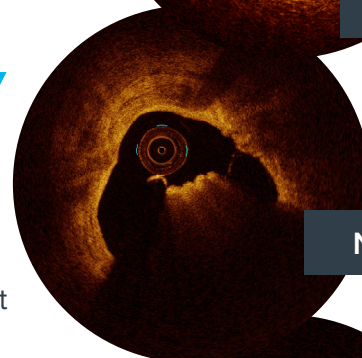
Stent Expansion

0%

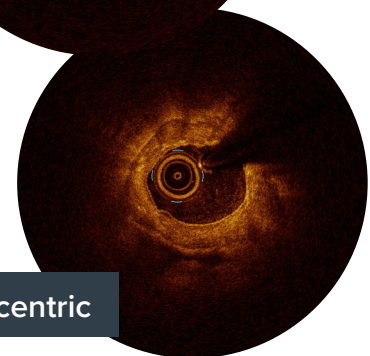
Procedural Complications



Eccentric



Nodular



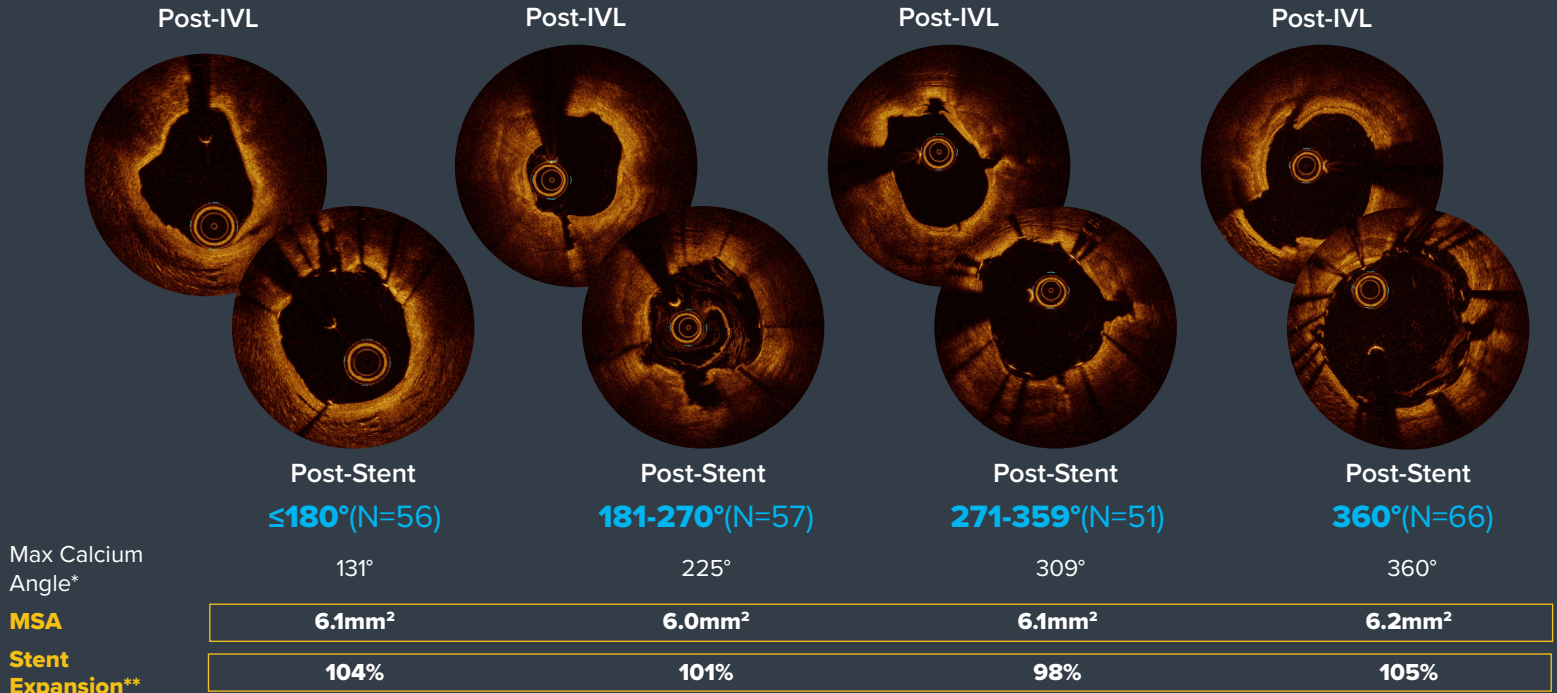
Concentric

Key Findings

1. Due to its unique MOA, IVL achieved consistent, excellent MSA & stent expansion across nodular, eccentric and concentric calcified lesions
2. MSA and stent expansion were consistent regardless of calcium burden or whether visible fractures were identified under OCT
3. Restoration of vascular compliance was achieved in challenging eccentric & nodular lesions without any procedural complications

Consistent in Eccentric & Concentric Calcium

MSA and Stent Expansion are Similar Across Different Calcium Arc Groups



Max Calcium Angle*

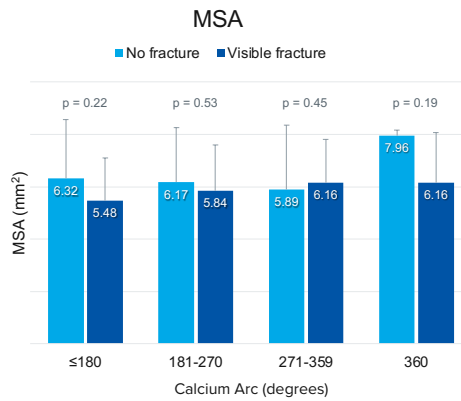
MSA

Stent Expansion**

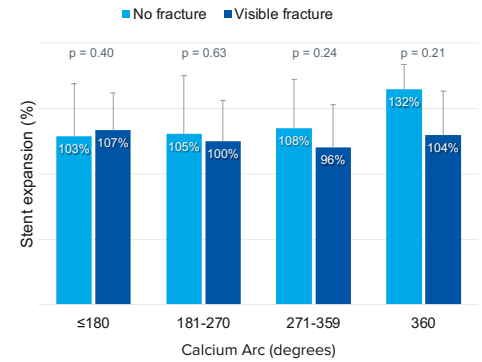
*Continuous calcium angle was defined as the maximum uninterrupted calcium angle observed in the lesion and was used to define the category assignment.

**Maximum Calcification Site

MSA and Stent Expansion are Similar Regardless of Visible Fracture Detection by OCT

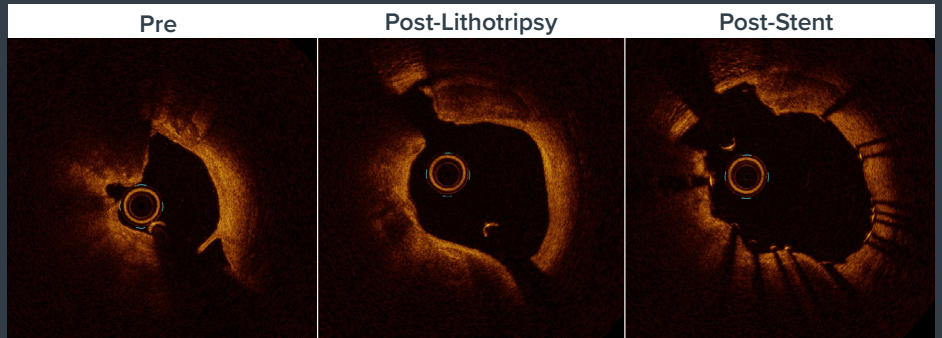
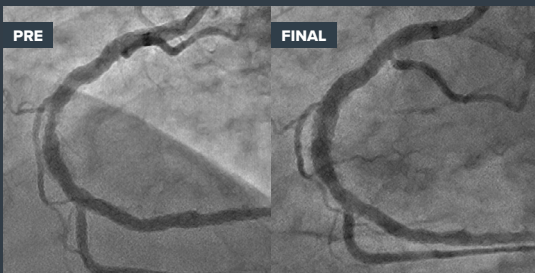


Stent Expansion at Max Calcium Site



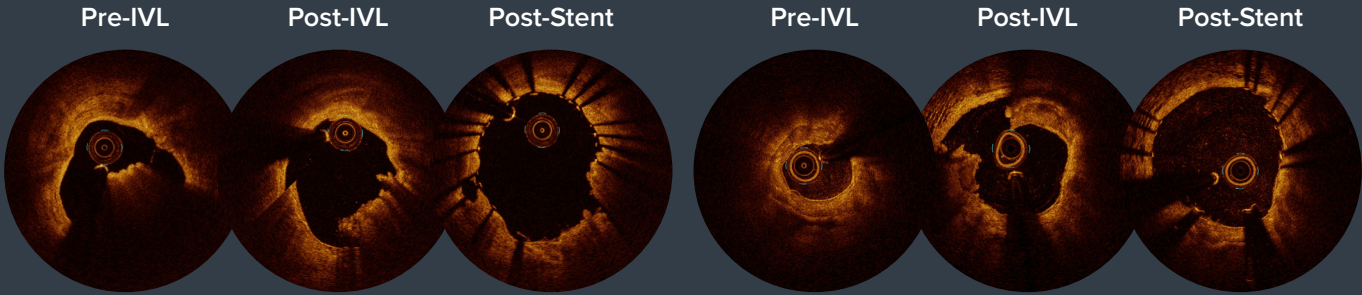
Eccentric Calcium Fracture Visualization with OCT Post IVL Therapy

Continuous Ca 180°-270°



Consistent in Calcium With or Without Nodules

Similar Post-IVL OCT Findings Regardless of Calcified Nodule* Presence



Calcific Nodules (N=54)

Lesions Without Calcific Nodules (N=194)

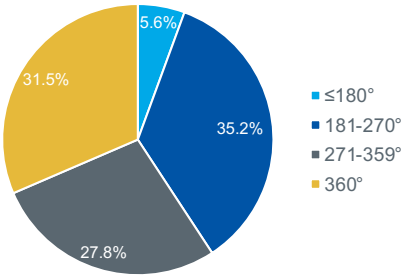
MSA	6.3mm ²	6.0mm ²
Stent Expansion**	101%	103%

*Calcium nodule was defined as an accumulation of nodular calcification (small calcium deposits) with disruption of fibrous cap on the calcified plate
**Maximum Calcification Site

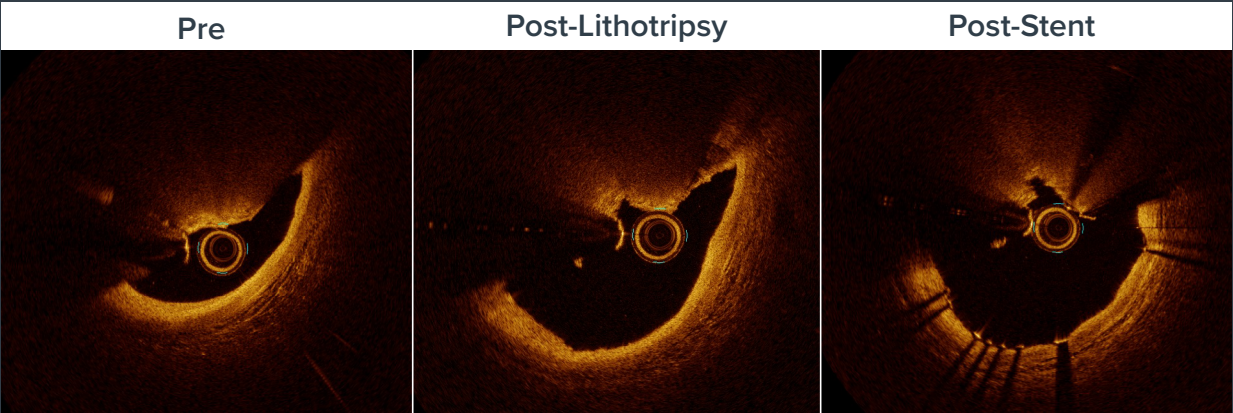22%

of lesions contain calcific nodules, most often found in concentric calcium with an overall greater burden of calcium

Association of Calcific Nodule with Maximum Calcium Angle

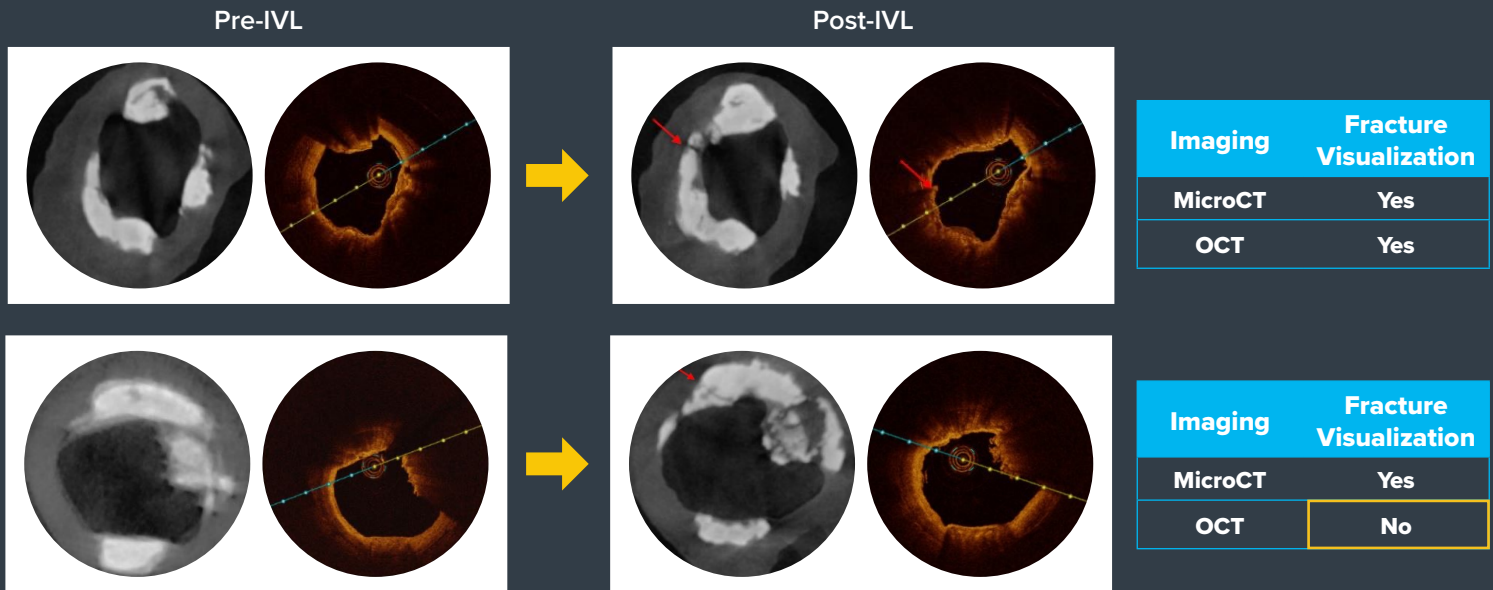


Calcified Nodule Fracture Visualization by OCT Post-IVL



Micro-fracture Visualization by MicroCT

OCT Not Able to Detect Subtle Micro-fractures in Calcific Plaque



Courtesy of Renu Virmani, CV Path Institute

Important Safety Information

Please contact your local Shockwave representative for specific country availability and refer to the Shockwave C², Shockwave S⁴, Shockwave M⁵ and Shockwave M⁵⁺ instructions for use containing important safety information.

Coronary Important Safety Information

In the United States: Rx only.

Indications for Use—The Shockwave Intravascular Lithotripsy (IVL) System with the Shockwave C² Coronary IVL Catheter is indicated for lithotripsy-enabled, low-pressure balloon dilatation of severely calcified, stenotic *de novo* coronary arteries prior to stenting.

Contraindications—The Shockwave C² Coronary IVL System is contraindicated for the following: This device is not intended for stent delivery. This device is not intended for use in carotid or cerebrovascular arteries.

Warnings— Use the IVL Generator in accordance with recommended settings as stated in the Operator's Manual. The risk of a dissection or perforation is increased in severely calcified lesions undergoing percutaneous treatment, including IVL. Appropriate provisional interventions should be readily available. Balloon loss of pressure was associated with a numerical increase in dissection which was not statistically significant and was not associated with MACE. Analysis indicates calcium length is a predictor of dissection and balloon loss of pressure. IVL generates mechanical pulses which may cause atrial or ventricular capture in bradycardic patients. In patients with implantable pacemakers and defibrillators, the asynchronous capture may interact with the sensing capabilities. Monitoring of the electrocardiographic rhythm and continuous arterial pressure during IVL treatment is required. In the event of clinically significant hemodynamic effects, temporarily cease delivery of IVL therapy.

Precautions— Only to be used by physicians trained in angiography and intravascular coronary procedures. Use only the recommended balloon inflation medium. Hydrophilic coating to be wet only with normal saline or water and care must be taken with sharp objects to avoid damage to the hydrophilic coating. Appropriate anticoagulant therapy should be administered by the physician. Precaution should be taken when treating patients with previous stenting within 5mm of target lesion.

Potential adverse effects consistent with standard based cardiac interventions include— Abrupt vessel closure – Allergic reaction to contrast medium, anticoagulant and/or antithrombotic therapy-Aneurysm-Arrhythmia-Arteriovenous fistula-Bleeding complications-Cardiac tamponade or pericardial effusion-Cardiopulmonary arrest-Cerebrovascular accident (CVA)-Coronary artery/vessel occlusion, perforation, rupture or dissection-Coronary artery spasm-Death-Emboli (air, tissue, thrombus or atherosclerotic emboli)-Emergency or non-emergency coronary artery bypass surgery-Emergency or non-emergency percutaneous coronary intervention-Entry site complications-Fracture of the guide wire or failure/malfunction of any component of the device that may or may not lead to device embolism, dissection, serious injury or surgical intervention-Hematoma at the vascular access site(s)-Hemorrhage-Hypertension/Hypotension-Infection/sepsis/fever-Myocardial Infarction-Myocardial Ischemia or unstable angina-Pain-Peripheral Ischemia-Pseudoaneurysm-Renal failure/insufficiency-Restenosis of the treated coronary artery leading to revascularization-Shock/pulmonary edema-Slow flow, no reflow, or abrupt closure of coronary artery-Stroke-Thrombus-Vessel closure, abrupt-Vessel injury requiring surgical repair-Vessel dissection, perforation, rupture, or spasm.

Risks identified as related to the device and its use: Allergic/immunologic reaction to the catheter material(s) or coating-Device malfunction, failure, or balloon loss of pressure leading to device embolism, dissection, serious injury or surgical intervention-Atrial or ventricular extrasystole-Atrial or ventricular capture.

Prior to use, please reference the Instructions for Use for more information on warnings, precautions and adverse events. <https://shockwavemedical.com/IFU>

Please contact your local Shockwave representative for specific country availability and refer to the Shockwave C² instructions for use containing important safety information.

References

*Moderated Poster, TCT 120: Optical Coherence Tomography Characterization of Shockwave Intravascular Lithotripsy for Treatment of Calcified Coronary Lesions: Patient-level Pooled Analysis of the Disrupt CAD OCT Sub-studies, Ziad A. Ali, TCT 2021.

+Moderated Poster, TCT 121: Intravascular Lithotripsy is Effective in the Treatment Calcified Nodules: Patient-level Pooled Analysis From the Disrupt CAD OCT Sub-studies, Ziad A. Ali, TCT 2021.