

American Quarter Horse



Anatomy

External Features

Muscles

Organs

Skeleton

Foot

Teeth

AMERICAN
QUARTER
HORSE
ASSOCIATION

American Quarter Horse



The conformation of an American Quarter Horse is different than that of any other breed. This booklet is designed to aid you in becoming familiar with the conformation standards and anatomical structure of the breed.

AMERICAN
QUARTER
HORSE
ASSOCIATION

AMERICAN
QUARTER
HORSE
YOUTH
ASSOCIATION

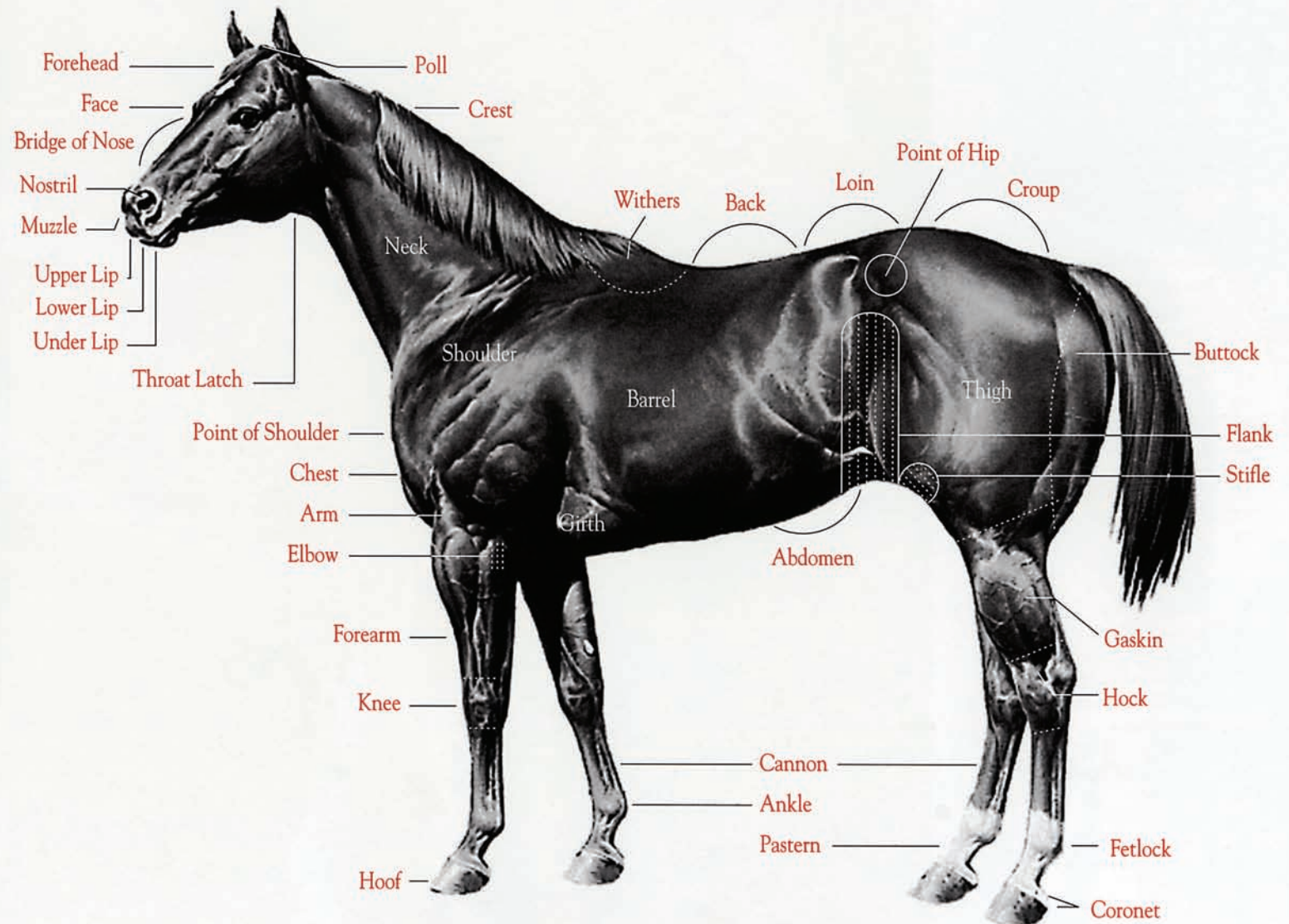


American Quarter Horse



External

This chart shows the points of a horse. Knowledge of points is of great importance when making application to register an animal with the American Quarter Horse Association.

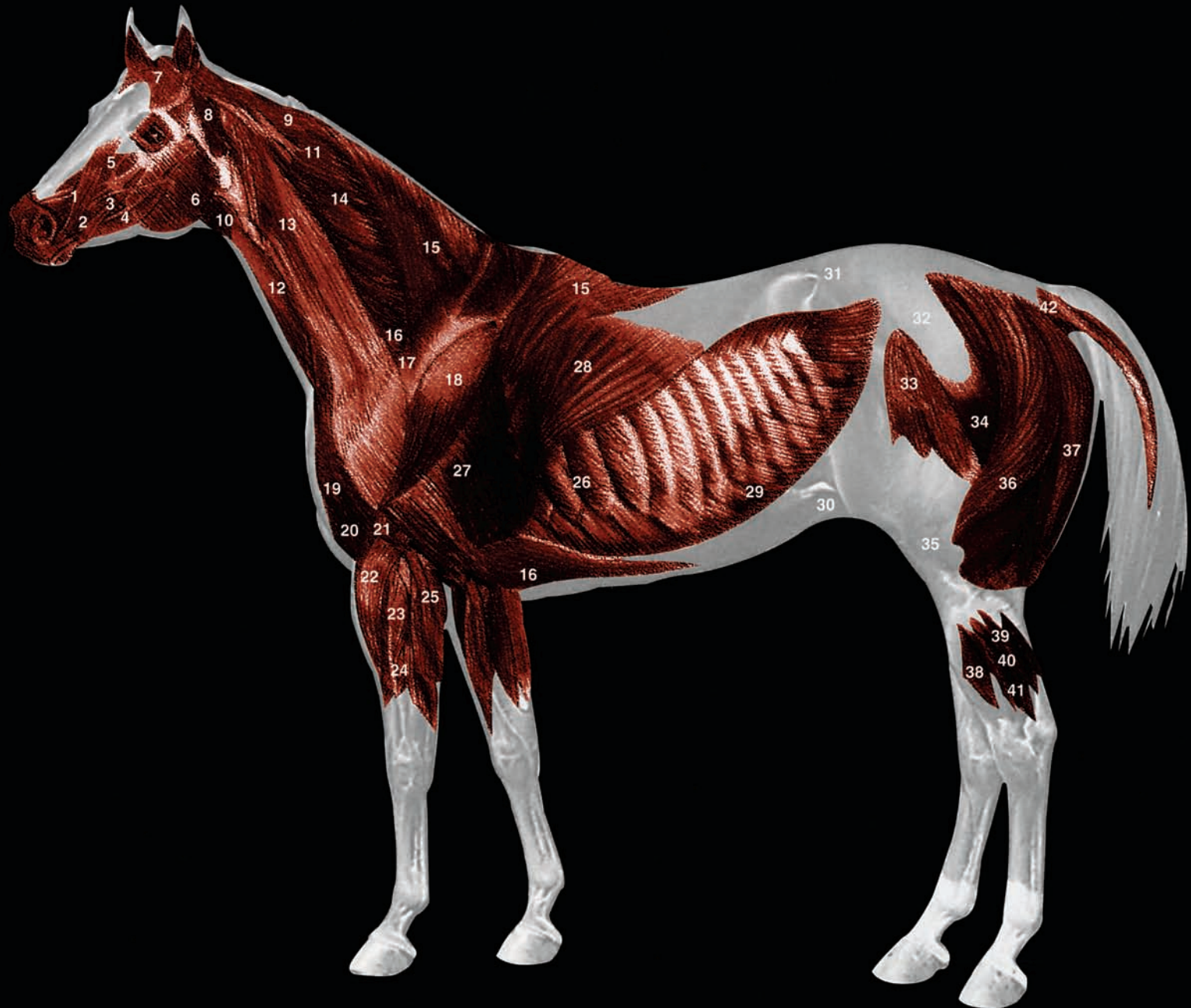



American Quarter Horse

Muscles

1. Levator nasolabialis
2. Zygomaticus
3. Buccinator
4. Facial vein
5. Levator labii sup. proprius
6. Masseter
7. Scutularis
8. Parotido-auricularis
9. Rhomboideus
10. Jugular vein
11. Splenius
12. Sterno-cephalicus
13. Brachiocephalicus
14. Serratus cervicis
15. Trapezius
16. Pectorals, deep
17. Supraspinatus
18. Deltoid
19. Pectorals, superficial
20. Biceps brachii
21. Brachialis
22. Ext. carpi radialis
23. Common digital ext.
24. Deep flexor
25. Ulnaris lateralis
26. Serratus thoracis
27. Triceps brachii
28. Latissimus dorsi
29. Obl. abdominis ext.
30. Aponeurosis of obl. abd. ext.
31. Lumbodorsal fascia
32. Gluteal fascia
33. Tensor fascia latae
34. Gluteus superficialis
35. Fascia lata
36. Biceps femoris
37. Semitendinosus
38. Long digital extensor
39. Soleus
40. Lat. digital extensor
41. Gastrocnemius
42. Saccrocoecygeus

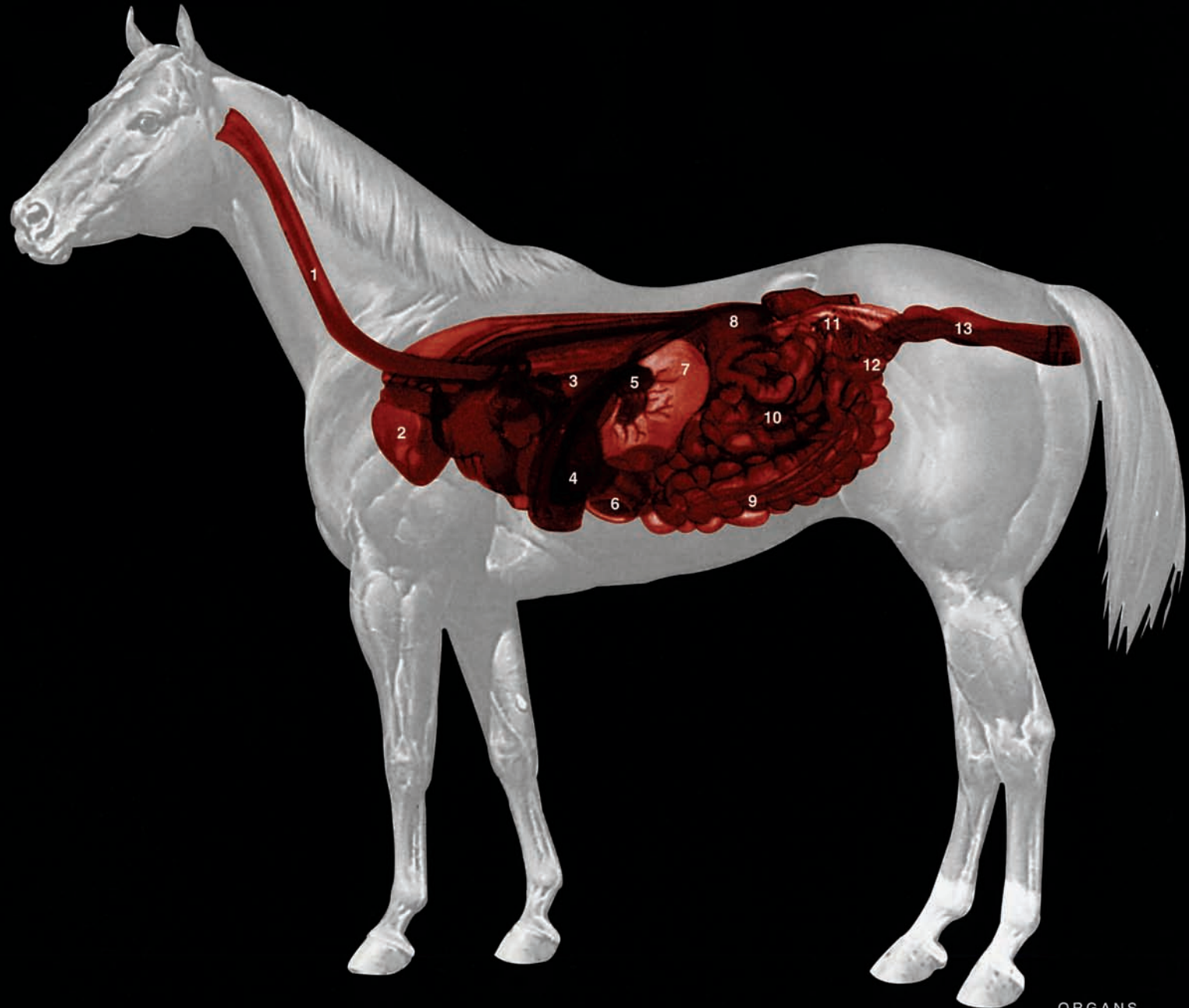




American Quarter Horse

Organs

1. Esophagus
2. Lung, right
3. Diaphragm (cut border)
4. Liver
5. Pancreas
6. Colon, ventral (right)
7. Stomach
8. Kidney, right
9. Cecum
10. Intestine, small
11. Ovary, right
12. Uterine (fallopian) tube, right
13. Rectum





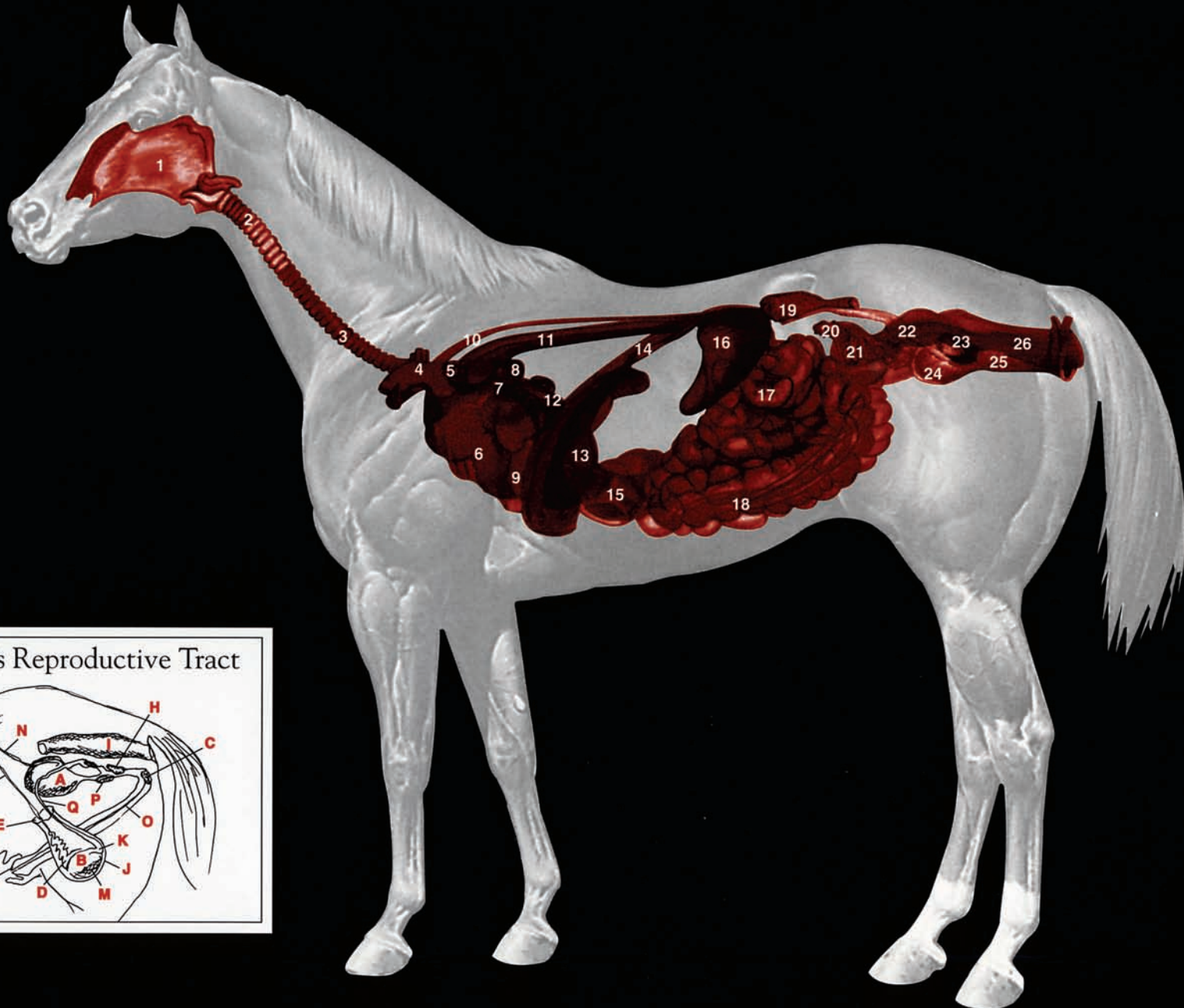
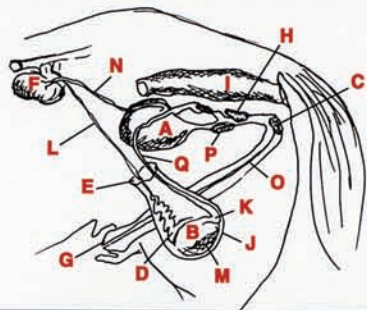
American Quarter Horse

Organs

1. Pharynx
2. Thyroid gland
3. Trachea
4. Brachiocephalic trunk
5. Vena cava, anterior
6. Heart
7. Pulmonary artery (cut)
8. Bronchus, left (cut)
9. Coronary artery, left
10. Thoracic duct
11. Aorta, thoracic
12. Vena cava, posterior
13. Liver
14. Diaphragm, (cut border)
15. Intestine, large (colon)
16. Spleen
17. Intestine, small
18. Colon, ventral (left)
19. Kidney, left
20. Ovary, left
21. Uterine (fallopian) tube, left
22. Ureter, left
23. Cervix
24. Urinary bladder
25. Urethra
26. Vagina

- A. Bladder
- B. Body of Epididymis
- C. Bulbourethral Gland
- D. Head of Epididymis
- E. Inguinal Ring
- F. Kidneys
- G. Penis
- H. Prostate Gland
- I. Rectum
- J. Scrotum
- K. Tail of Epididymus
- L. Testicular Vessels
- M. Testis
- N. Ureter
- O. Urethra
- P. Vesicular Gland
- Q. Vas Deferens

Stallion's Reproductive Tract

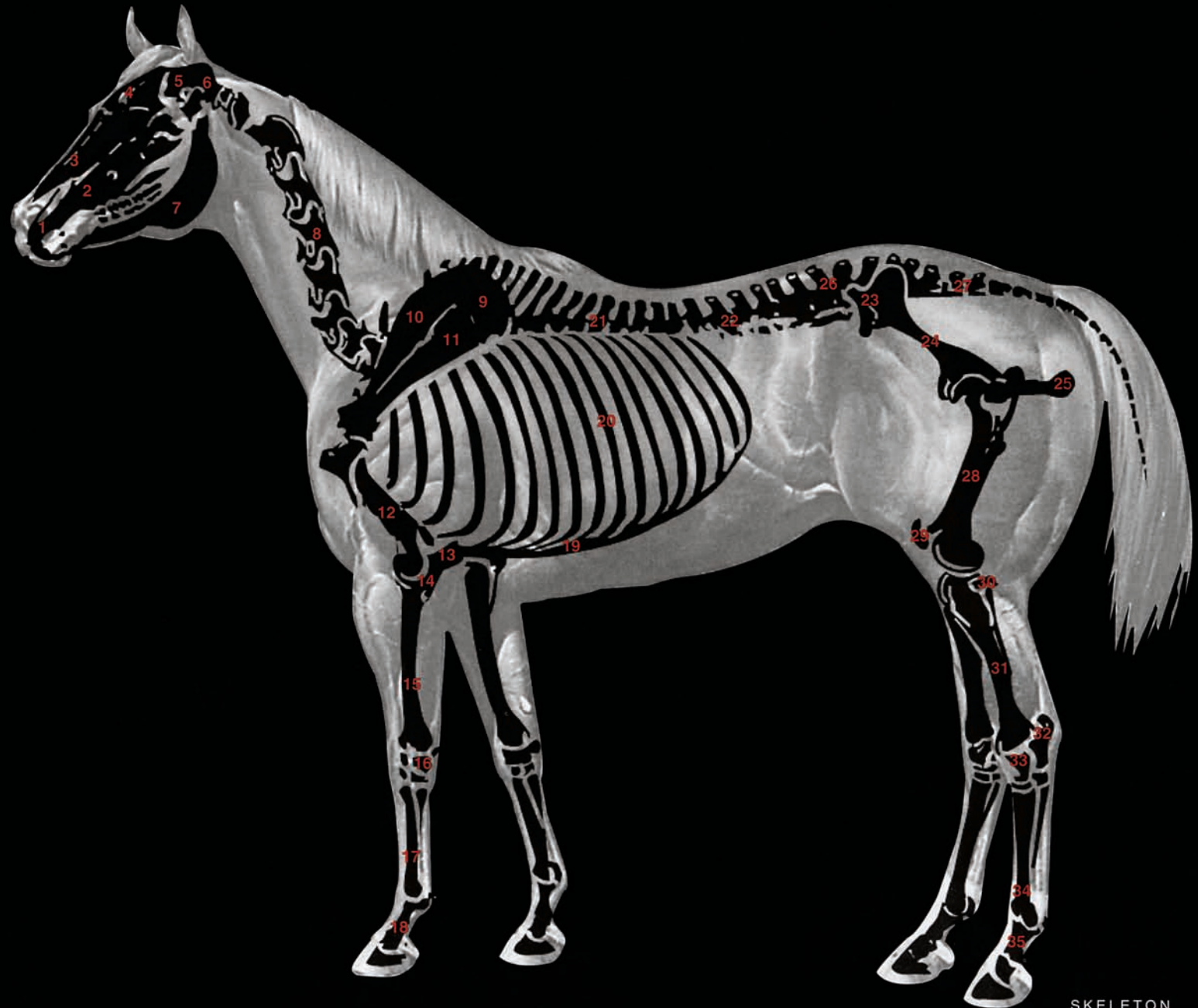




American Quarter Horse

Skeleton

1. Premaxilla
2. Maxilla
3. Nasal
4. Frontal
5. Parietal
6. Occipital
7. Mandible
8. Cervical vertebrae
9. Cartilage of scapula
10. Scapular spine
11. Scapula
12. Humerus
13. Olecranon
14. Ulna
15. Radius
16. Carpus
17. Metacarpals
18. Phalanges of forefoot
19. Costal cartilages
20. Ribs (18)
21. Thoracic vertebrae
22. Lumbar vertebrae
23. Pubis
24. Ilium
25. Ischium
26. Sacrum
27. Coccygeal vertebrae
28. Femur
29. Patella
30. Fibula
31. Tibia
32. Tuber Calcis
33. Tarsus
34. Metatarsus
35. Phalanges of hindfoot

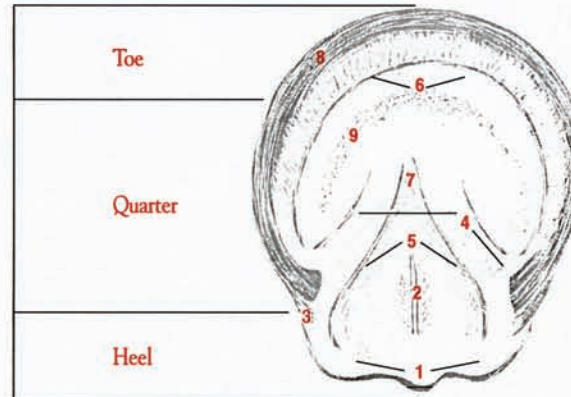




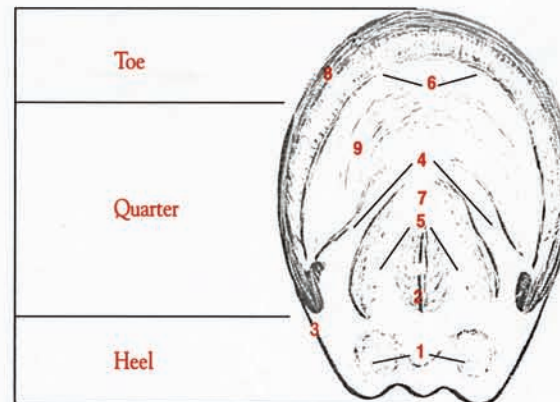
Lower Leg and Foot

Normal Forefoot

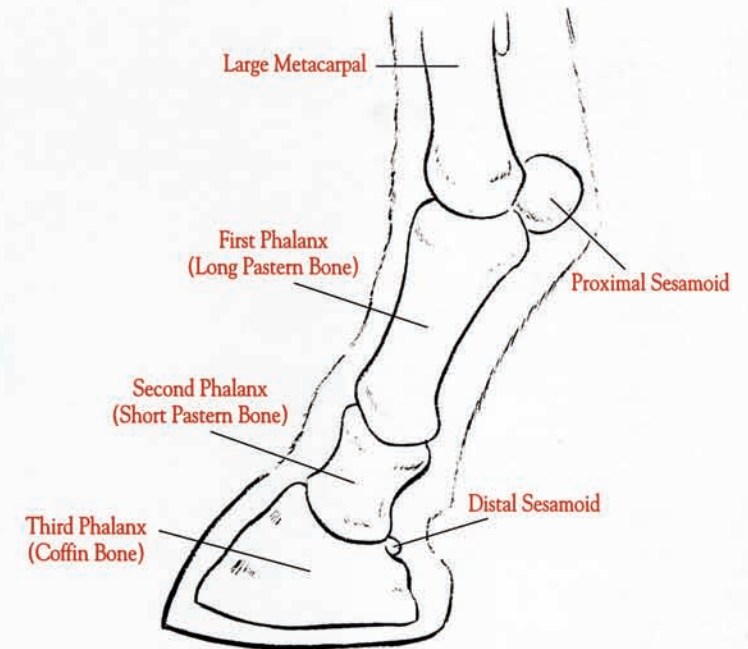
1. Bulbs
2. Central sulcus of frog (spine of frog) (frog stay)
3. Angle of wall
4. Bars
5. Collateral sulcus
6. White Line
7. Apex of frog
8. Wall
9. Sole



Normal Hindfoot



Lateral View of Lower Leg Bones





Glossary of Terms

Cup. The dark or dark-brown to black cavity in the infundibulum.

Deciduous teeth. Temporary, fetal, milk or baby teeth. They are characterized primarily by their smaller size, constricted neck and shallow cup.

Dental star. The darker dentin that fills the pulp cavity as the tooth wears. It is dark yellow to yellowish-brown.

Dental table. The table, masticatory or occlusal surface.

Eruption. Pertains to the period when a tooth breaks through the gum.

Galvayne's groove. The longitudinal depression on the labial surface of the upper corner (I3) incisor. The cementum remains in the groove as a dark line; the rest of the surface is worn to expose the white enamel.

Incisor teeth. Starting at the midline incisors are designated as centrals (I1), intermediates (I2) and corners (I3).

Infundibulum. The deep invagination of enamel which is filled with a variable amount of cement. Commonly referred to as the "cup."

Labial surface. Surface toward the lips.

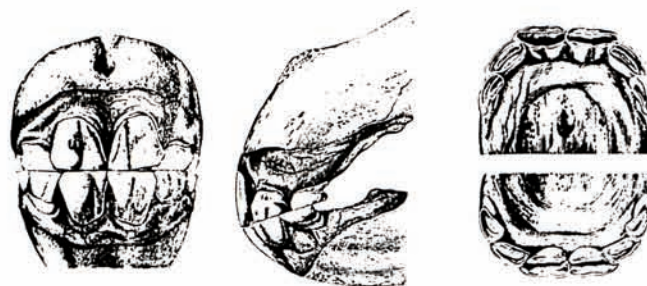Lingual surface. Surface toward the tongue.

Permanent teeth. Second dentition or adult teeth.



One Year

Viewed from in front, all deciduous incisors are visible, the crown of the centrals and intermediates is fully exposed and the neck may be discernible. In profile, the upper and lower corner incisors are not in contact. The dental tables of the centrals show considerable wear. The dental star is seen usually in the centrals and intermediates as a dark or yellowish-brown transverse line in the dentin on the labial side of the infundibulum. The corner incisors are sharp.



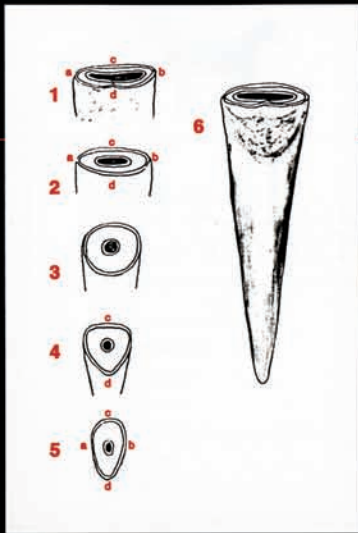
Three Years

Viewed from in front, the four permanent central incisors are seen just coming into wear. They appear more solid, have salient vertical ridges and grooves and are larger and broader than adjacent deciduous teeth. In profile, the deciduous intermediates appear pushed out and short. The neck is distinct on the intermediates and corners. The dental table of each central incisor has a deep cup and the borders of these teeth are sharp. The lower intermediates are smooth. The lower corners have little central enamel.

American Quarter Horse



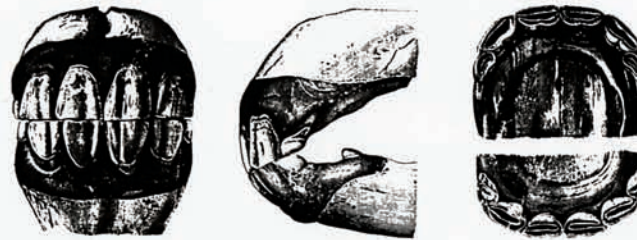Teeth Determining Age



Schematic Drawing of Central Incisor

Appearance of the table (occlusal surface) at different stages of wear.

1. Shortly after eruption its breadth (transverse, long diameter) marked by a-b, its thickness (short diameter) c-d.
2. Shows the table surface as it appears at the age of six years, the breadth a-b, begins to decrease, and the thickness, c-d, increases slightly; the tooth appears oval.
3. Shows a round surface of nine to twelve years. The two diameters become equal.
4. Shows a triangular surface of fourteen to seventeen years. The long diameter, c-d, in the labiolingual direction.
5. Shows surface of animal over twenty in which breadth, a-b, measures only half as much as thickness, c-d.
6. Depicts exposed incisor.



Four Years

View from in front, the permanent upper central and intermediate incisors are in contact with corresponding lower teeth. The jaws have acquired so much width for the centrals and intermediates that the deciduous corners can scarcely be seen. In profile, the corners appear very small; the upper corner is shown being pushed from its alveolus. In the lower jaw the canine is seen cutting the gum. (Canines may erupt as early as three and one-half years but usually at four years and three months and as late as five years.) The Dental tables of the centrals show wear but their cups are deep. The intermediates are in wear but sharp; the deciduous upper corners show a portion of their roots exposed.

Five Years

Permanent dentition is complete; all teeth are in wear. Viewed from in front, the jaws appear convex in both directions. In profile, they have a similar disposition. The canines have erupted completely. The dental tables of the centrals and intermediates are wide transversely, show wear, but their cups are readily visible and completely encircled by the central enamel. The corners are commencing to wear at their labial border. (It is imperative that the form and dimensions of the central enamel be considered carefully.)

Courtesy of American Association of Equine Practitioners

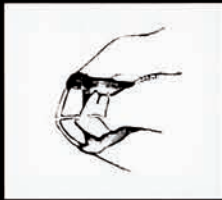

Profile of Upper Corner Incisor

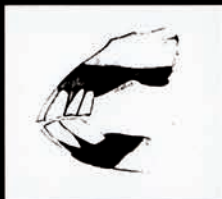Galvayne's Groove



Nine to Ten Years — Galvayne's groove appears at the gum margin.



Fifteen Years — Galvayne's groove extends halfway down the labial surface of incisor.

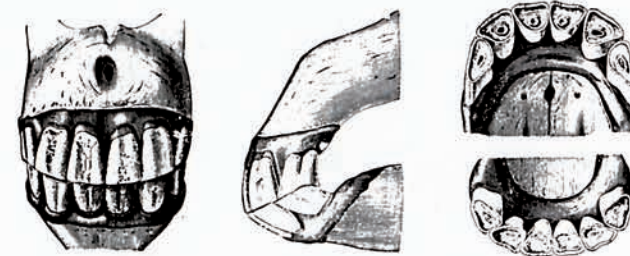


Twenty Years — Galvayne's groove extends the entire length of the labial surface.



Seven Years

Viewed from in front, the teeth may appear whiter due to wearing of the cement although some teeth remain stained. In profile, the dental table of the lower corner incisor is narrower than that of the upper; this results in a notch upon the upper corner incisor, the seven year hook or notch. The incident angle of the incisive arcades is less perpendicular than at six years. The dental tables of the lower centrals and intermediates are smooth, cups for practical purposes are no longer present. The ring of central enamel is narrower from side to side and nearer the lingual border. The lower corners still retain their cups.



Fifteen Years

Viewed from in front, the lower incisors may appear shorter than the uppers depending upon the angle from which they are observed. (This will vary depending upon height of horse and examiner.) In profile, the incisors appear to be about the same length. Galvayne's groove extends halfway down the labial surface of the upper corner incisor; the corner notch is often present. The dental tables of the lower centrals appear triangular, the intermediates are round to triangular and all lower incisors show in their center a dark, distinct, round dental star.

AMERICAN
QUARTER
HORSE
ASSOCIATION

P.O. Box 200 ■ Amarillo, Texas 79168
(806) 376-4811 ■ <http://www.aqha.com>