

Telemetered Left-Ventricular Pressure in Yucatan Mini-Pigs: Chronic Evaluation in a Novel Genetic Model of Non-Obstructed Hypertrophic Cardiomyopathy

Beth Geist¹, Bradley L. Youngblood¹, Yukie Ueyama¹, Amanda LaRose¹, Robert Hamlin¹, Marc J. Evanchik², Carlos del Rio^{1,2}
¹QTest Labs, Columbus, OH; ²MyoKardia, San Francisco, CA

INTRODUCTION & METHODS

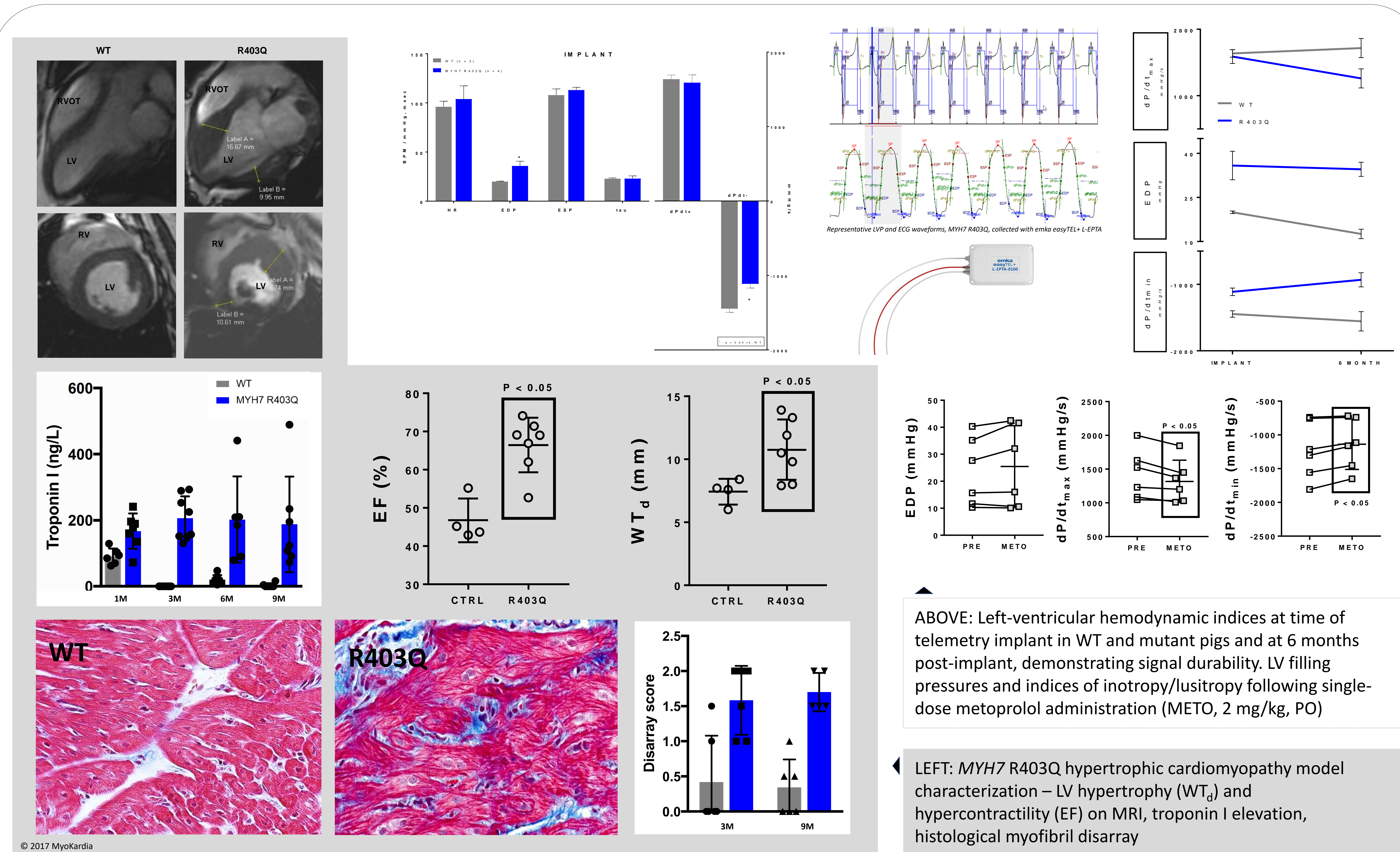
Mini-pigs are a popular model for safety pharmacology pre-clinical evaluations, and recent advances permit their genetic manipulation in order to study states of cardiovascular dysfunction. However, the feasibility of telemetered left-ventricular pressure-assessments, particularly in the setting of induced cardiomyopathy remains to be explored. For these in vivo experiments, juvenile Yucatan mini-pigs with a heterozygous *MYH7* R403Q mutation (n = 4) and wild-type (WT, n = 3) herd-mates were instrumented for left-ventricular pressure (LVP) and ECG telemetry via a left-lateral thoracotomy (emka easyTEL+ L-EPTA).

RESULTS

Following recovery from surgical instrumentation, all pigs had waveforms suitable for analysis. Healthy WT pigs had LVP parameters within physiologic ranges (HR: 96±6 bpm, EDP: 20±0.4 mmHg, ESP: 108±6 mmHg, dPdt_{max}: 1636±56 mmHg/s, dPdt_{min}: -1446±49 mmHg/s, tau: 23±1 msec). Meanwhile, age-matched mutant pigs with hypertrophic cardiomyopathy (HCM, n = 4) exhibited the anticipated LVP alterations, including elevated filling pressures (EDP: 36±5 mmHg) and impaired indices of relaxation (dPdt_{min}: -1112±57 mmHg/s). At approximately 6 months post-implantation, telemetry signals remained adequate to permit phenotype differentiation (e.g., EDP: 13±2 mmHg in WT, 35±2.4 mmHg in HCM pigs). At this time, left-ventricular telemetered signals were sensitive to the effects of acute metoprolol administration (2 mg/kg PO, MET), showing, for instance, reductions in dPdt_{max} (-7±2%) and HR (-5±1%).

CONCLUSION

Taken together, these results indicate the utility and durability of telemetered left-ventricular pressure in the mini-pig, in both health and in the presence of a novel phenotype of cardiac dysfunction.



ABOVE: Left-ventricular hemodynamic indices at time of telemetry implant in WT and mutant pigs and at 6 months post-implant, demonstrating signal durability. LV filling pressures and indices of inotropy/lusitropy following single-dose metoprolol administration (METO, 2 mg/kg, PO)

LEFT: *MYH7* R403Q hypertrophic cardiomyopathy model characterization – LV hypertrophy (WT_d) and hypercontractility (EF) on MRI, troponin I elevation, histological myofibril disarray