

Key words: wound healing, pressure ulcers, decubitus ulcers, MLS laser therapy, open wound healing, dogs

MLS laser Therapy in dogs with pressure ulcers and open wound: case reports.

L. Dragone^a, S. Palladini^a, and M. Glazar^b,

a) Ambulatorio Veterinario “Dog Fitness”, Reggio Emilia, Italy

b) ASA, Vicenza, Italy

ABSTRACT

The aim of this report is to describe the clinical application of MLS Laser Therapy as adjuvant therapeutic technique in combination with topical wound management for treatment of pressure ulcers and open wound in four dogs.

The dogs have sustained trauma, were hospitalized in the physical therapy veterinary clinic and had wounds that had to be treated concurrently with neurologic conditions. Pressure ulcers and open wound were managed by topical wound medications and contemporaneously were irradiated twice daily with MLS pulse. The wounds were measured at the beginning of the treatment and at the end of the therapy and showed a reduction in size during the course of treatments.

MLS laser therapy may be useful as adjuvant therapeutic technique for treatment of decubitus ulcers and open wounds in dogs.

INTRODUCTION

Management of wounds is an important part of physical therapy and rehabilitation in humans and animals. Patients that have sustained trauma often have wounds that must be treated concurrently with other conditions. Proper wound care, along with some of the newer modalities,

as laser therapy, should be applied for successful treatment of open wounds. Many veterinary patients have orthopedic or neurologic conditions that result in prolonged recumbency, placing them at risk for decubital ulcers. When these wounds occur, appropriate treatment is critical to limit morbidity [1].

Some wounds fail to progress in an orderly and timely manner through the biologic sequences comprising the phases of healing, resulting in a non healing or poorly healing wound. The location of a wound over a bony surface or joint may result in delayed healing owing to difficulty in maintaining approximation of found edges [1]. A pressure sore or decubital ulcer is localized injury to the skin and/or underlying tissue usually over a bony prominence, as a result of pressure, or pressure in combination with shear, resulting in local or regional tissue ischemia [2]. The progression of pressure sores is influenced by several other factors like direct pressure, including shear forces, friction and moisture [3,4,5]. Underlying conditions, such as neurologic injuries (paralysis), vascular diseases causing impaired circulation, metabolic diseases (diabetes mellitus or hyperadrenocorticism), and malnutrition, can place animals at much greater risk for the development of pressure sores. Most pressure sores observed in veterinary

medicine occur in nonambulatory patients or in patients that cannot or are unwilling to change their body position [1]. Common anatomic locations for pressure sores include the greater trochanter, tuber ischium, calcaneus, lateral malleolus of the tibia, and the lateral aspect of the fifth digit of the paw in the pelvic limbs and the acromion, olecranon, and lateral epiconyle of the humerus, and the lateral aspect of the fifth digit of the paw in the thoracic limbs [1].

Prevention of pressure sores is certainly more cost effective than treating them; however, this is often easier said than done. The prevalence of pressure sores in people in the United states is reported to be between 1.3 to 3 million, and pressure sores are estimated to affect 5% to 10% of hospitalized patients [6,7]. Pressure sores are a source of numerous complications contributing to high rates of morbidity and mortality in humans. Treatment of pressure sores can result in huge costs to the health care system [3,7,8]. Although similar statistics are not available in veterinary medicine, pressure sores are similarly known to be a cause of increased patient morbidity and expense to the owner.

National Pressure Ulcer Advisory Panel (NPUAP) and European Pressure Ulcer Advisory Panel (EPUAP) developed a common international definition and classification system for pressure ulcers in humans [2]. These classification schemes are used to determine treatment protocols and can similarly be applied to animals. According to International Pressure Ulcer Classification System four levels of injury are described (Tab. I).

During the past 30 years there have been numerous reports indicating the potential of laser biostimulation in the facilitation of the wound healing process. In vitro data suggest that laser therapy facilitates collagen synthesis [9], keratinocyte cell motility [10], and growth factor release [11], transforms fibroblasts to myofibroblasts [12] and accelerates angiogenesis [13,31]. Many authors of clinical studies have reported the benefits of low level laser

Category/Stage	Description
Category/Stage I	Non-blanchable erythema Intact skin with non-blanchable redness of a localized area usually over a bony prominence. The area may be painful, firm, soft, warmer or cooler as compared to adjacent tissue
Category/Stage II	Partial thickness Partial thickness loss of dermis presenting as a shallow open ulcer with a red pink wound bed, without slough. May also present as an intact or open/ruptured serum-filled or sero-sanguinous filled blister. Presents as a shiny or dry shallow ulcer without slough or bruising
Category/Stage III	Full thickness skin loss Full thickness tissue loss. Subcutaneous fat may be visible, but bone, tendon or muscle are not exposed. Slough may be present, but does not obscure the depth of tissue loss. May include undermining and tunneling. The depth of a Category/Stage III pressure ulcer varies by anatomical location. Bone/tendon is not visible or directly palpable.
Category/Stage IV	Full thickness tissue loss Full thickness tissue loss with exposed bone, tendon or muscle. Slough or eschar may be present. Often includes undermining and tunneling. The depth of a Category/Stage IV pressure ulcer varies by anatomical location. Category/Stage IV ulcers can extend into muscle and/or supporting structures (e.g. fascia, tendon or joint capsule) making osteomyelitis or osteitis likely to occur. Exposed bone/muscle is visible or directly palpable.

Tab. 1. International Pressure Ulcer Classification System

therapy (LLLT) on tissue healing, but others have shown no effect [14-16]. The data from appropriately designed studies indicated that LLLT should be considered as an adjuvant therapy for refractory wound-healing disorders, including in diabetic patients, although many of the in vivo studies lacked specific information on dosimetric data and appropriate controls [17]. LLLT also resulted beneficial in treating difficult wounds in metabolically compromised patients, as it was demonstrated in a study on wound healing in diabetic rats [18], while another study reviewed the literature regarding the overall treatment effects of laser phototherapy on tissue repair and concluded that LLLT represented an effective treatment [19]. To our knowledge, until today only one previous report has been published on the clinical application of laser therapy to promote closure of chronic skin wound in a dog [20].

This case report describes the clinical use of MLS laser therapy as adjuvant therapeutic technique in three dogs with pressure ulcers developed as a consequence of neurologic disorders and in a dog with an

open skin wound followed by secondary closure. The dogs were hospitalized in a veterinary physiotherapy and rehabilitation center in Reggio Emilia and the rehabilitation program and wound management were performed one/twice day by veterinarians.

MLS Laser Therapy was carried out using a MLS M1 vet laser device (ASA, Arcugnano (Vi), Italy), equipped with synchronized combination of continuous and pulsed emissions. Continuous emission was produced by an InGa(Al)As laser with the following parameters: wavelength 808 nm; maximum power 1000 mW; continuous wave; spot area 3,14 cm². Pulsed emission was produced by an InGaAs/GaAs laser with the following parameters: wavelength 905 nm; maximum power 25 W; pulse frequency 2000 Hz; pulse duration 200 ns; spot area 3,14 cm². MLS laser treatment was performed on the wounds every day, after cleaning procedure and before applying topical wound management products.

The wounds were cleaned with chlorhexidine gel and the medication was done by applying products for topical wound management.

Case 1

An eight-year-old male mixed breed dog, weighing 13 kg, was presented in the clinic after the right hemilaminectomy at T12 to T13 performed for intervertebral disk disease. The examination revealed a non-ambulatory paraparesis and bilateral tuber ischium stage III pressure ulcers developed because the dog was allowed to drag itself only on his front paws. The wounds were full thickness, 2,1 x 2,1 cm on the left tuber ischium, 1,9 x1,9 cm on the right tuber ischium, but bone was not exposed (Fig. 1). The dog was hospitalized and put on the rehabilitation programme consisting in hydrotherapy and passive and active exercises repeated twice daily. The pressure sores were treated with MLS Laser Therapy and topical wound medications two times a day.

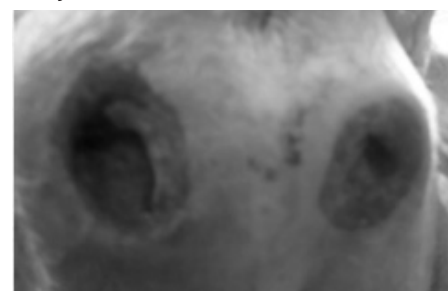


Fig. 1. decubitus ulcers at the first examination in a mixed breed dog

The ulcers were thoroughly cleansed with Clorexyderm Spot Gel (ICF, Cremona, Italy), treated with MLS laser therapy (Contaminated Wound Healing programme, continuous wave, scanning mode, time 2 minutes, energy delivered 126,9 J) and then dressed topically with Repty Gel (Innovet, Saccolongo, Italy). The irradiation field included the entire

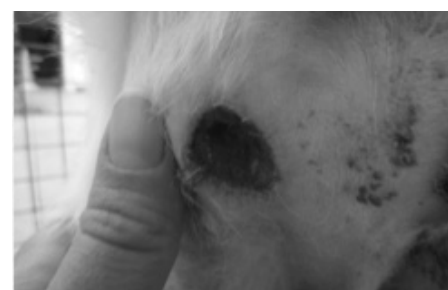

Fig. 2. decubitus ulcers 12 days after treatment onset

wound plus a 2 cm margin around the wound. Treatments were given for 12 consecutive days and pressure sores were measured twice, once at the beginning of the treatment and at the 12th day of the treatment. At the second measurement the dimensions of the ulcers were 1,2 x 1,2 cm for the left ulcer and 1,3 x 1,3 cm for the right ulcer and the depth of the wounds was diminished (Fig. 2, 3). The dimensions of the wounds were reduced by 42,8% and 31,6% respectively in 12 days.

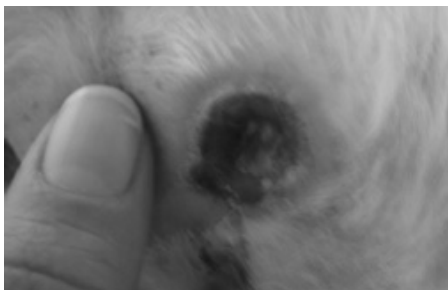


Fig. 3. decubitus ulcers 12 days after treatment onset

Case 2

A thirteen-year-old female mixed breed dog, weight 32 kg, was presented in the clinic after the right hemilaminectomy performed at T3 to T7 for discospondylitis. The patient was severely paraparetic and non-ambulatory. It presented category IV pressure ulcer on the right great trochanter. Initially, the pressure ulcer was 1,5 cm wide (Fig. 4). The patient was hospitalized, put on the rehabilitation programme that included hydrotherapy and passive and active exercises performed two times a day and started the antibiotic therapy with clindamycin 11 mg/kg BID.

The pressure sore was treated with

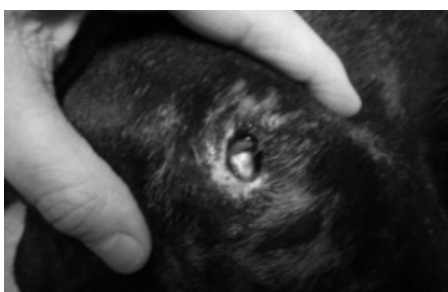


Fig. 4. great trochanter pressure sore at the first examination

MLS Laser Therapy and topical wound medications twice daily. The ulcer was thoroughly cleansed with Clorexyderm Spot Gel (ICF, Cremona, Italy), treated with MLS laser therapy (Contaminated Wound Healing programme, continuous wave, scanning mode, time 2 minutes, energy delivered 126,9 J) all over the wound and on the margin of the wound and then dressed topically with a solution of Betadine (Viatrix, Milano, Italy) and sugar. The second measurement of the pressure ulcer, 4 days after the first measurement, revealed a reduction of the wound dimensions from 1,5 cm to 1 cm (33,3%) (Fig. 5).

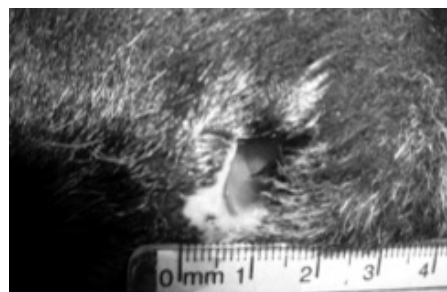


Fig. 5. pressure sore 4 days after onset of therapy

Case 3

A ten years old male Dobermann, weight 30 kg, was examined in the clinic after the ventral slot performed at C5 to C6 and at C6 to C7 for Wobbler syndrome. At the reception the dog was severely tetraparetic, non-ambulatory, not able to stand and presented noticeable muscle atrophy of the shoulders and hind legs and maintained constantly the lateral recumbency, although the recumbency was changed every 4 hours. The patient started the rehabilitation programme including hydrotherapy and passive and active exercises twice daily. The pressure ulcers at both great trochanters were developed 1 month after the admission to the clinic. Initially, the diameter of the right decubitus ulcer was 5 cm and of the left decubitus 4,6 cm (Fig. 6). The ulcers were thoroughly cleansed with Clorexyderm Spot Gel (ICF, Cremona, Italy), treated with MLS laser therapy (Contaminated Wound Healing

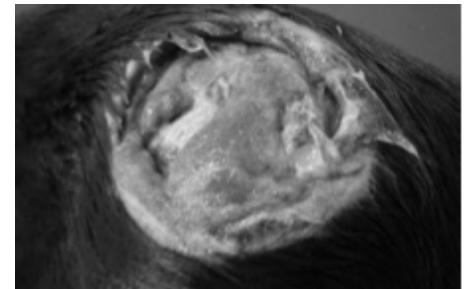


Fig. 6. great trochanter decubitus ulcer at the first examination

programme, continuous wave, scanning mode, time 2 minutes, energy delivered 126,9 J) and then dressed topically with a solution of Betadine (Viatrix, Milano, Italy) and sugar. The irradiation field included the entire wound plus a 2 cm margin around the wound. After 5 days of MLS laser therapy and topical wound management the diameter decreased to 4,5 cm on the right and to 4,1 on the left trochanter. After 10 days of treatment the diameter of the right decubital ulcer was 4,1 cm and 3,9 cm of the left one. After 18 days of therapy the dimensions of the wound decreased further to 3,6 cm on the right side and to 2,9 cm on the left side (Fig. 7). In 48 days of therapy the ulcer on the right trochanter was reduced by 28% and on the left trochanter by 36,9%.

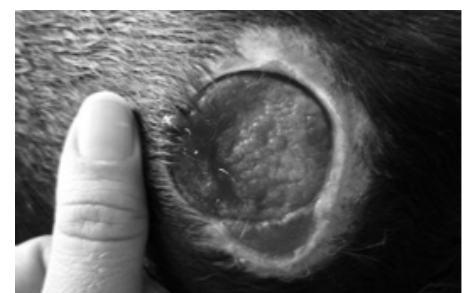


Fig. 7. the ulcer after 48 days of treatment

Case 4

A three years old male mixed breed dog, weight 26 kg, was examined in the clinic after the stabilisation of the vertebral fracture and luxation at T2 to T3 and the amputation of the second digit of the right hind limb. At the reception the dog was tetraparetic and non-ambulatory. The patient was hospitalized, put on the

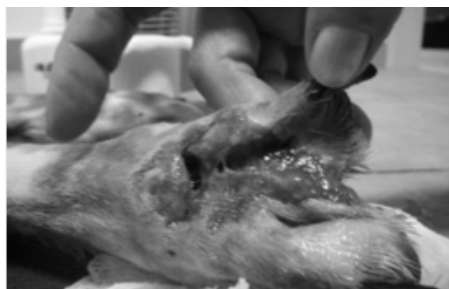

Fig. 8. chronic wound on the right hind limb, after the amputation of one digit

rehabilitation programme that included hydrotherapy and passive and active exercises performed two times a day and started the antibiotic therapy with clindamycin 11 mg/kg BID. The skin lesion that developed in situ of the amputation had to close by second intention healing and was managed as open wound (Fig. 8). The wound was treated with MLS Laser Therapy and topical wound medications twice daily. It was thoroughly cleansed with Clorexyderm Spot Gel (ICF, Cremona, Italy), treated with MLS laser therapy (Contaminated Wound Healing programme, continuous wave, scanning mode, time 2 minutes, energy delivered 126,9 J) all over the wound and on the margin of the wound and then dressed topically with Hypermix (RI. MOS., Modena, Italy). The wound healed completely after 32 days of therapy (Fig. 9, 10).

DISCUSSION

Wound healing is a biologically complex sequence of overlapping events and is a natural restorative response to tissue injury [1]. The dynamic series of interrelated processes is divided into the inflammatory, proliferative and remodelling phases. The duration of each stage will vary with the wound type, management, microbiologic and other physiologic factors [21]. Each phase involves biochemical mediators such as cytokines, growth factors, and other cellular components that stimulate or inhibit the cellular responses that facilitate healing [1]. The biologic process for wound healing is the same for all wounds, although the specific mechanisms may vary. Superficial and partial-thickness wounds complete

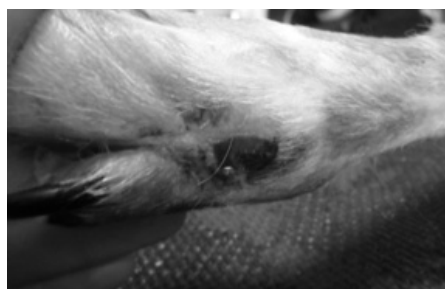

Fig. 9. the wound 15 days after treatment onset



Fig. 10. the wound after 32 days of therapy. Note that the wound has completely healed.

healing principally through epithelialization and progress through the repair process more quickly than full thickness wounds that rely primarily on contraction. Chronic wounds may lack an orderly progression through wound healing phases, allowing for prolonged inflammation, repeated injury, and infection [1]. Many of the regimens and therapeutic interventions designed to facilitate the wound healing process, as laser therapy, influence the various phases of the process. Methods to promote wound healing must not interrupt these biological processes.

Laser therapy is thought to stimulate wound healing by inducing vasodilatation that increases nutrients and growth factors supplies, activates fibroblasts and increases collagen synthesis, an essential protein for tissue repair and regeneration [22,23]. In damaged tissues, where recovery of nervous functions is normally slow, laser stimulation accelerates nervous cells regeneration, revitalising the insensitive areas [24,25,26]. It also induces lymphatic and vascular regeneration [27,28,29] and increases and accelerates angiogenetic processes [13,30]. Finally, laser therapy prevents the formation of hyperkeratotic lesions formation because it reduces the

formation of cicatricial tissue following a skin lesion [31].

To authors' knowledge, in veterinary medicine only one report on laser therapy in wound healing in a dog has been published [20] and our aim with this case reports was to present our experience with MLS laser therapy used as adjuvant therapy for decubitus ulcers and wound healing in unfavorable conditions for healing. In the cases presented in this report, the MLS laser therapy was used in combination with topical wound management to promote healing and to accelerate the formation of cicatricial tissue in decubitus ulcers and an open wound. The four dogs in this case series showed deep pressure ulcers and a chronic open wound and all cases followed the process of second intention healing. All dogs have sustained trauma and had wounds that had to be treated concurrently with other conditions. Hydrotherapy was included in the rehabilitation programme of all dogs and it probably represented a delaying factor in the healing process, as hydrotherapy is usually contraindicated when there is a presence of infected skin lesions. However, considering the concurrent illness of the patients and the benefits of aquatic exercise in their conditions, it was decided that the delayed healing of the ulcers and wounds was a minor problem that could be handled with MLS laser therapy and topical wound medication. The patients did not show signs of discomfort during the treatments and the therapy was easy to handle and quick to perform.

In summary, we consider MLS laser therapy an effective and valid adjuvant therapy for refractory wound healing disorders as decubitus ulcers and open wounds that have to heal by second intention in dogs, even in conditions that delay healing as those experienced during the treatment of our patients. However, the advantage of the laser therapy to promote wound healing has still not been unequivocally established by appropriate studies in veterinary medicine. For veterinary patients, carefully designed clinical trials using laser therapy for treatment of open wounds or decubitus ulcers may help define its effectiveness.

REFERENCES

1. Hanks J, Spodnick G. Wound healing in the veterinary rehabilitation patient. *Vet Clin Small Anim*, 2005, 35: 1453-1471
2. European Pressure Ulcer Advisory Panel and National Pressure Ulcer Advisory Panel. Prevention and treatment of pressure ulcers: quick reference guide. Washington DC: National Pressure Ulcer Advisory Panel. 2009.
3. Sørensen JL, Jørgensen B, Gottrup F. Surgical treatment of pressure ulcers. *Am J Surg*, 2004, 188 (1A Suppl): 42-51
4. Brem H, Lyder C. Protocol for the successful treatment of pressure ulcers. *Am J Surg*, 2004, 188 (1A Suppl): 9-17
5. Edlich RF, Winters KL, Woodward CR, et al. Pressure ulcer prevention. *J Long Term Eff med Implants*, 2004, 14(4): 285-304
6. Lyder CH. Pressure ulcer prevention and management. *JAMA*, 2003, 289:223-6
7. Allman RM, Laprade CA, Noel LB, et al. Pressure sores among hospitalized patients. *Ann Intern Med*, 1986, 105:337-42
8. O'Brien SP, Gahtan V, Wind S, et al. What is the paradigm: hospital or home health care for pressure ulcers? *Am Surg*, 1999, 65:303-6
9. Abergel RP, Meeker CA, Lam TS, Dwyer RM, Lesavoy MA, Uitto J. Control of connective tissue metabolism by lasers: recent developments and future prospects. *J Am Acad Dermatol*, 1984, 11: 1142-150
10. Haas AF, Isseroff RR, Wheeland RG, Rood RA, Graves PJ. Low energy helium-neon laser irradiation increases the motility of human keratinocytes. *J Invest Dermatol*, 1990, 94: 822-26
11. Yu W, Naim JO, Lanzafame RJ. The effects of photo-irradiation on the secretion of TGF and PDGF from fibroblasts in vitro. *Lasers Surg Med Suppl*, 1994, 6:8
12. Pourreau-Schneider N, Ahmed A, Soundry M, et al. Helium-neon laser treatment transforms fibroblasts into myofibroblasts. *Am J Path*, 1990, 137: 171-78
13. Mirsky N, Krispel Y, Shoshany Y, Maltz L, Oron U. Promotion of angiogenesis by low energy laser irradiation. *Antioxid Redox Signal*, 2002, 4(5): 785-90
14. Allendorf JD, Bessler M, Huang J et al. Helium-neon laser irradiation at fluences of 1, 2 and 4 J/cm² failed to accelerate wound healing as assessed by wound contracture rate and tensile strength. *Lasers Surg Med*, 1997, 20: 340-45
15. Hunter J, Leonard L, Wilson R, Snider G, Dickson J. Effects of low energy laser on wound healing in a porcine model. *Lasers Surg Med*, 1984, 3: 285-90
16. Saperia D, Glassberg E, Lyons RF. Demonstration of elevated type I and III procollagen mRNA level in cutaneous wounds treated with helium-neon laser: Proposed mechanism for enhanced wound healing. *Biochem and Biophysical Res Comm*, 1986, 138: 1123-28
17. Schindl A, Schindl M, Pernerstorfer-Schoen H, et al. Low intensity laser therapy in wound healing: a review with special respect to diabetic angiopathies. *Acta Chir Aust*, 2001, 33(3): 132-7
18. Reddy GK, Stehno-Bittel L, Enwemeka CS. Laser photostimulation accelerates wound healing in diabetic rats. *Wound Repair Regen*, 2001, 9(3): 248-55
19. Enwemeka CS, Parker JC, Dowdy DS, et al. The efficacy of low-power lasers in tissue repair and pain control: a meta-analysis study. *Photomed Laser Surg*, 2004, 22(4): 323-9
20. Lucroy MD, Edwards BF, Madewell BR. Low-intensity laser light-induced closure of a chronic wound in a dog. *Vet Surg*, 1999, 28:292-95
21. Wound management. In: Aiello S, Mays A, eds. *The Merck veterinary manual*. Eight edition. Whitehouse Station: Merck & Co. Inc, 1998, pp 1255
22. Almeida-Lopes L, Rigau J, Zângaro RA, Guidugli-Neto J, Jaeger MM. Comparison of the low level laser therapy effects on cultured human gingival fibroblasts proliferation using different irradiance and same fluence. *Lasers Surg Med*, 2001, 29(2): 179-84
23. Liu H, Dang Y, Wang Z, Chai X, Ren Q. Laser induced collagen remodeling: a comparative study in vivo on mouse model. *Lasers Surg Med*, 2008, Jan;40(1): 13-9
24. Rochkind S, Ouaknine GE. New trend in neuroscience: low-power laser effect on peripheral and central nervous system (basic science, preclinical and clinical studies). *Neurol Res*, 1992, 14: 2-11
25. Gigo-Benato D, Geuna S, Castro Rodrigues A, Fornaro M, Boux E, Battiston B, Tos P. Low-power laser biostimulation enhances nerve repair after end-to-side neurotomy: a double-blind randomized study in the rat median nerve model. *Lasers in Med Science*, 2004, 19: 57-65
26. Rochkind S, Leider-Trejo L, Nissan M, Shamir MH, Kharenko O, Alon M. Efficacy of 780-nm Laser Phototherapy on Peripheral Nerve Regeneration after Neurotube Reconstruction Procedure (Double-Blind Randomized Study). *Photomedicine and Laser Surgery*, 2007, 25(3): 137-143
27. Maier M, Haina D, Landthaler M. Effect of low energy laser on the growth and regeneration of capillaries. *Laser in Medical Science*, 1990, 5(4): 381-386
28. Rebeiz E, April MM, Bohigian RK, Shapshay SM. Nd-YAG laser treatment of venous malformations of the head and neck: an update. *Otolaryngol Head Neck Surg*, 1991, 105(5):655-61
29. Goldman MP, Fitzpatrick RE, Ruiz-Esparza J. Treatment of port-wine stains (capillary malformation) with the flashlamp-pumped pulsed dye laser. *J Pediatr*, 1993, 122(1):71-7
30. Garavello I, Baranauskas V, da Cruz-Höfling MA. The effects of low laser irradiation on angiogenesis in injured rat tibiae. *Histol Histopathol*, 2004, 19(1):43-8
31. Alster T, Zaulyanov L. Laser scar revision: a review. *Dermatol Surg*, 2007, 33(6):770